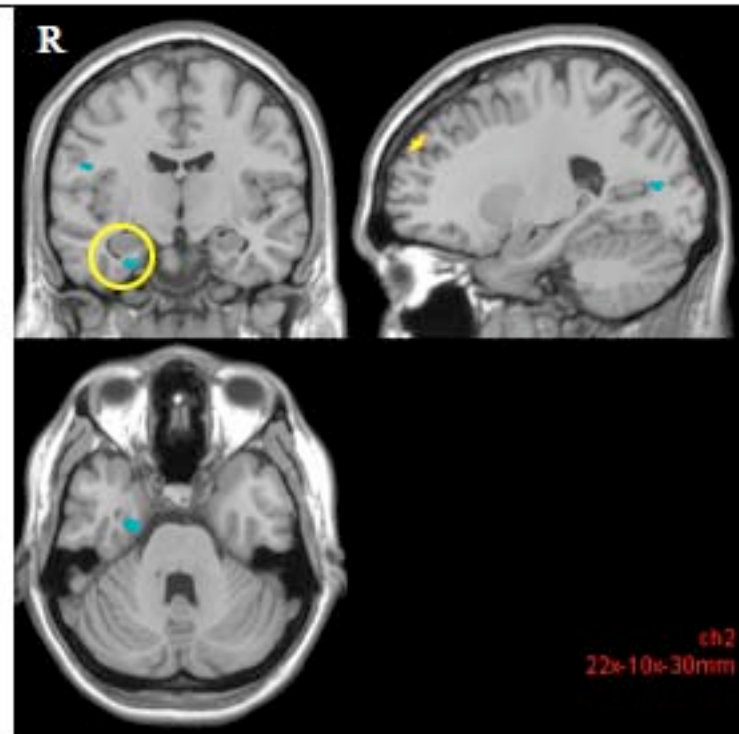


A. R Parahippocampal Gyrus



B. L Ventral Striatum

