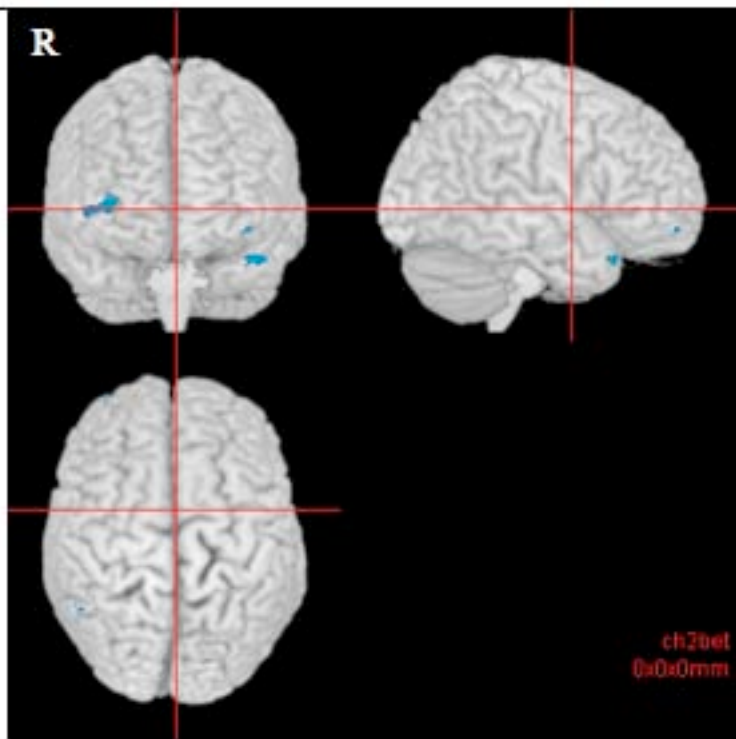


A. Fronto-temporal areas



B. R Parahippocampal Gyrus

